Western Medicine&Dentistry
Schulich School of Medicine & Dentistry

To seed or not to seed:
A single-institution experience of radioactive seed localization

K. Jumaa, B. Al Johani, M. Brackstone, A. Kornecki

Department of Medical Imaging, Schulich School of Medicine and Dentistry, Western University, London, Canada

Introduction

Preoperative localization of nonpalpable breast cancers is commonly accomplished with hooked wires under either ultrasound or stereotactic guidance.

Inherent drawbacks to this method include preoperative migration, inefficacy for superficial lesions, and patient discomfort. At our centre, another hindrance to this method is the scheduling conflicts and inefficiencies as a result of necessitating insertion on the same day of a planned lumpectomy.

Iodine-125 (I-125) radioactive seed localization (RSL) is quickly gaining popularity as a safe and reliable method of preoperative breast localization for nonpalpable breast lesions (1-3). Recent studies point to its superiority over traditional wire localization (WL) with respect to accuracy of lesion localization and decreased need for re-excision (4-7). RSL has also demonstrated improved patient satisfaction and comfort (7,8).

RSL was introduced in our center six years ago and has now surpassed WL as the localization method of choice by the majority of our surgeons: we present our experience.



Two radioactive seeds are shown relative to the index finger for scale.

Results

Time to surgery

For malignant lesions, the mean time from diagnosis to surgery was 42.6 ± 18.8 days for WL patients and 39.0 ± 15.0 days for RSL patients (P = 0.06).
All WL were inserted the day of surgery. The mean time from RSL insertion to surgery was 4.0 ± 2.8 days (range 0-17).

Specimen X-rays

Specimen X-rays were obtained in 233/292 (80%) cases with WL 194/194 (100%) cases with RSL (P < 0.001).

Seed migration and seed loss

The seed fell out of the specimen during surgery in 6/194 (3.1%) cases.
Over 1 cm seed migration was observed in 2/194 (1.0%) cases. No seed loss was recorded.

Specimen X-ray confirms harvesting of both the radioactive seed and cluster of calcifications (centre). Three surrounding surgical

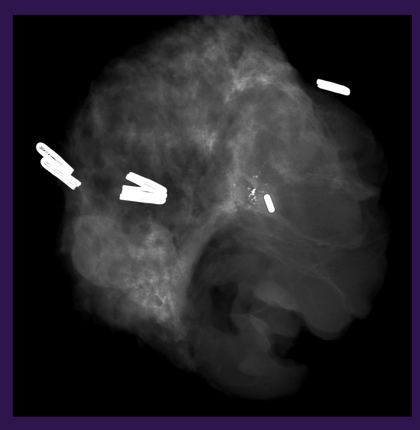

Specimen size

For malignant lesions, the average specimen size was 6.8 cm ± 2.8 cm for WL and 6.9 ± 2.9 cm for RSL (P = 0.5).

Surgical margins

Positive margins were present in 34/198 (17.2%) cases with WL and 15/146 (10.3%) cases with RSL (P < 0.001).
Close margins (≤ 1 mm) were present in 31/198 (15.6%) cases with WL and 1/146 (0.7%) cases with RSL (P < 0.001)

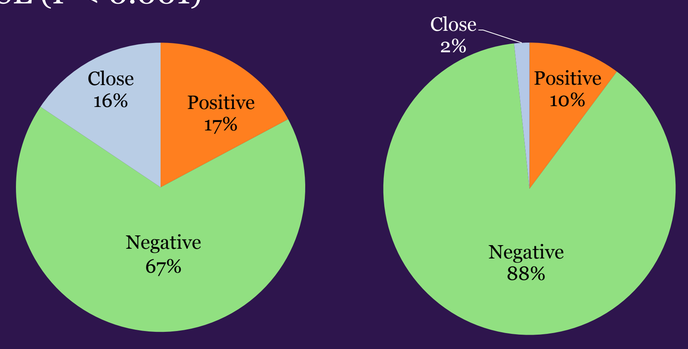

Surgical margins with WL (left) and RSL (right)

Number of surgeries

The surgeons who transitioned to RSL showed a 37.3% average increase in the number of surgeries performed per year (P < 0.001) in 2016 compared to 2013. The only surgeon who continued to use WL performed 47 lumpectomies in 2013 and 45 in 2016.

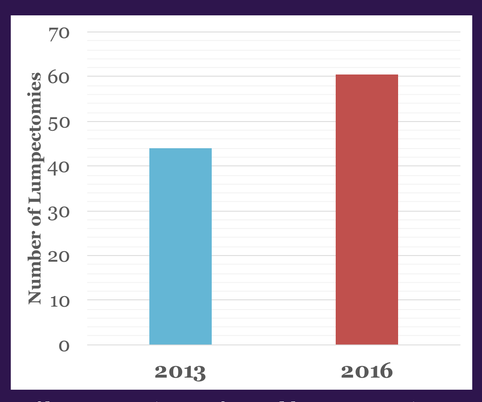

Total number of lumpectomies performed by surgeons in 2013 and 2016

Materials and Methods

A retrospective observational study at a single academic institution involving total of 548 localization procedures performed in 2013 and in 2016.

There were 486 eligible patients: 292 WL procedures in 2013 and 194 RSL procedures in 2016.

Electronic patient records, pathology reports, and specimen X-rays were reviewed.

The following were recorded for each localization procedure:

- time from diagnosis to surgery
- time from localization to surgery
- resection margins (positive, close, negative)
- specimen size
- seed migration or loss
- surgeon performing the resection
- pre- and post-operative histology

Specimen X-rays were reviewed by a fellowship-trained breast imaging specialist (A.K.) with 13 years of experience to assess for seed migration.

Significant seed migration was defined as migration of over 1 cm on specimen X-ray when compared to the post-localization mammogram.

Positive margins were defined as tumour at ink.

Close margins were defined as less than or equal to 1 mm.

Discussion

Our results demonstrate multifactorial superiority of RSL over traditional WL.

Firstly, our study identifies significantly (P < 0.001) fewer pathologically involved margins in the RSL group, unlike recent studies (1, 2, 8, 9, 13-17) which found no difference.

Next, we observed a 19% increase in compliance with intraoperative specimen X-rays with RSL, presumably related to radiation safety concerns. An added benefit is the facilitated communication between radiologists and surgeons, providing a second "checkpoint" to ensure the lesion is adequately resected.

A trend towards reduced specimen sizes have been reported previously with RSL (20-22), which other groups have attributed to point-source guidance provided by the seed. However, unlike prior studies (6, 13, 14) we have shown an associated difference in margin status despite similar specimen sizes between the WL and RSL.

Finally, RSL increased the overall efficiency by improving scheduling flexibility in our department and optimizing operating room resources. At our centre, surgeons who transitioned to RSL showed a 37.3% increase in the mean number of lumpectomies performed in 2016 compared to 2013 without any increase in dedicated operating time (P = 0.001). There was no significant change in the number of lumpectomies performed by one surgeon who continued to use WL.

Conclusion

Switching to RSL results in increased surgical efficiency, improved scheduling flexibility, and a reduction in the number of pathologically involved margins.

References

1. Sung JS, King V, Thornton CM, Brooks JD, Fry CW, El-Tamer M, et al. Safety and efficacy of radioactive seed localization with I-125 prior to lumpectomy and/or excisional biopsy. EJR 2013; 82:1453–7.
2. Bloomquist E V, Ajkay N, Patil S, Collett AE, Frazier TG, Barrio A V. A Randomized Prospective Comparison of Patient-Assessed Satisfaction and Clinical Outcomes with Radioactive Seed Localization versus Wire Localization. Breast J 2016; 22:151–7.
3. McGhan LJ, McKeever SC, Pockaj BA, Wasif N, Giurescu ME, Walton HA, et al. Radioactive seed localization for nonpalpable breast lesions: review of 1,000 consecutive procedures at a single institution. Ann Surg Oncol 2011; 18:3096–101.
4. Gray RJ, Pockaj BA, Karstaedt PJ, Roarke MC. Radioactive seed localization of nonpalpable breast lesions is better than wire localization. Am J Surg 2004; 188:377–80.
5. Alderliesten T, Loo CE, Pengel KE, Rutgers EJT, Gilhuijs KGA, Vrancken Peeters MJTFD. Radioactive seed localization of breast lesions: An adequate localization method without seed migration. Breast J 2011; 17:594–601.
6. Stelle L, Schoenheit T, Brubaker A, Tang X, Qu P, Cradock K, et al. Radioactive Seed Localization Versus Wire Localization for Nonpalpable Breast Lesions: A Two-Year Initial Experience at a Large Community Hospital. Ann Surg Oncol 2018; 25:131–6.
7. Xu X jian, Li J jing, Ji W Bin. An updated Meta-Analysis of radioactive seed localization versus wire-guided localization in the treatment of nonpalpable breast lesions. Breast J 2018; 24:673–5.
8. Gray RJ, Salud C, Nguyen K, Dauway E, Friedland J, Berman C, et al. Randomized prospective evaluation of a novel technique for biopsy or lumpectomy of nonpalpable breast lesions: radioactive seed versus wire localization. Ann Surg Oncol 2001; 8:711–5.
9. Langhans L, Tvedskov TF, Klausen TL, Jensen M-B, Talman M-L, Vejborg I, et al. Radioactive Seed Localization or Wire-guided Localization of Nonpalpable Invasive and In Situ Breast Cancer: A Randomized, Multicenter, Open-label Trial. Ann Surg 2017; 266:29–35.
10. Johnson RB, Sun XL, Hockman MA, Villarreal EC, Wakulchik M, Wang QM. Randomized prospective evaluation of a novel technique for biopsy or lumpectomy of nonpalpable breast lesions: Radioactive seed versus wire localization. Ann Surg Oncol 2001; 8:711–5.
11. Chan KYB, WisebergFirtell JA, Jois HSR, Jensen K, Audisio RA. Localization techniques for guided surgical excision of non-palpable breast lesions. CDSR; Available from: http://ovidsp.ovid.com/ovidweb.cgi?T=JS&PAGE=reference&D=coch&NEWS=N&AN=00075320-100000000-07608. Available December 31, 2015. Accessed July 2, 2018.
12. Lovrics PJ, Cornacchi SD, Vora R, Goldsmith CH, Kahnamoui K. Systematic review of radioguided surgery for non-palpable breast cancer. Eur J Surg Oncol 201; 37:388–97.
13. Rarick J, Kimler BF, Tawfik O. Comparison of margin status and lesional size between radioactive seed localized vs conventional wire localized breast lumpectomy specimens. Ann Diagn Pathol 2016; 21:47–52.
14. Zhang Y, Seely J, Cordeiro E, Hefler J, Thavorn K, Mahajan M, et al. Radioactive Seed Localization Versus Wire-Guided Localization for Nonpalpable Breast Cancer: A Cost and Operating Room Efficiency Analysis. Ann Surg Oncol 2017; 24:3567–73.
15. Dryden MJ, Dogan BE, Fox P, Wang C, Black DM, Hunt K, et al. Imaging factors that influence surgical margins after preoperative 125I radioactive seed localization of breast lesions: Comparison with wire localization. AJR 2016; 206:1112–8.
16. Murphy JO, Moo TA, King TA, Van Zee KJ, Villegas KA, Stempel M, et al. Radioactive seed localization compared to wire localization in breast-conserving surgery: Initial 6-month experience. Ann Surg Oncol. 2013; 20:4121–7.
17. Velazco CS, Wasif N, Pockaj BA, Gray RJ. Radioactive seed localization for breast conservation surgery: Low positive margin rate with no learning curve. Am J Surg 2017; 214:1091–3.
18. Rhee D, Pockaj B, Wasif N, Stucky CC, Pizzitola V, Giurescu M, et al. Operative outcomes of conventional specimen radiography versus in-operating room specimen radiography in radioactive seed-localized segmental mastectomies. Am J Surg 2018; 215:151–4.
19. Diego EJ, Soran A, McGuire KP, Costellic C, Johnson RR, Bonaventura M, et al. Localizing High-Risk Lesions for Excisional Breast Biopsy: A Comparison Between Radioactive Seed Localization and Wire Localization. Ann Surg Oncol 2014; 21: 3268–72.
20. Janssen NNY, Nijkamp J, Alderliesten T, Loo CE, Rutgers EJT, Sonke JJ, et al. Radioactive seed localization in breast cancer treatment. Br J Surg 2016; 103:70–80.
21. Tran VT, David J, Patocskai E, Zummo-Soucy M, Younan R, Lalonde L, et al. Comparative Evaluation of Iodine-125 Radioactive Seed Localization and Wire Localization for Resection of Breast Lesions. CARJ 2017; 68:447–55.

St JOSEPH's HEALTH CARE LONDON

Schulich MEDICINE & DENTISTRY