Digital Breast Tomosynthesis with Photon-Counting technology: results from a clinical comparison study

Venturini E, Losio C, Rodighiero MG, Tacchini S, Schiani E, Panizza P
Breast Imaging Department - IRCCS San Raffaele Hospital –Vita-Salute San Raffaele University, Milan, Italy
venturini.elena@hsr.it

Purpose: Digital Breast Tomosynthesis (DBT) has been demonstrated to improve the sensitivity and specificity of 2D FFDM. Despite of the use of synthesized 2D images (s2D), the Average Glandular Dose (AGD) of DBT is slightly higher than 2D Full Field Digital Mammography (FFDM). Photon-Counting (PhC) technology may represent an interesting solution to overcome the concerns related to the radiation exposure increase of DBT.

PhC FFDM has been demonstrated to reduce the radiation dosage, while preserving a high diagnostic image quality. If applied to DBT, PhC technology may help to fully integrate DBT in the clinical practice.

Our purpose was to compare the image quality and the AGD of a new PhC DBT prototype with a commercially available conventional DBT system.

Methods: After ethical committee approval, women older than 40 years with a highly suspicious breast finding at clinical or imaging evaluation (BIRADS 4c or 5) underwent bilateral 2-view DBT with a conventional system and the PhC prototype, before breast biopsy.

Three readers with different experience (20, 10 and 5 years) independently compared the 3D and the s2D images giving a clinical (BI-RADS) and a conspicuity score for each suspicious breast finding.

The mammographic density was scored according to the ACR classification.

The AGDs of the 2 systems were recorded and compared.

Results: From December 2016 to October 2017 17 women (mean age 71 years; age range: 44 – 83 years) underwent bilateral 2-view DBT with both systems.

The density score was A-B for 9 women, C-D for the other 8 women according to the ACR classification.

In 15 exams, at least one suspicious finding was detectable by both systems.

Two exams were falsely negative with both systems due to high breast density and small cancer size.

All findings were confirmed as malignant.

There was no significant difference in density and BIRADS scores between the 2 systems.

Comparing the 3D images, the conspicuity of the findings was scored as equal or better for the PhC prototype in comparison to the other system in 95% observations.

Focusing on the s2D images, the conspicuity of findings was scored as equal or better for PhC prototype in comparison to the conventional system in 85% observations.

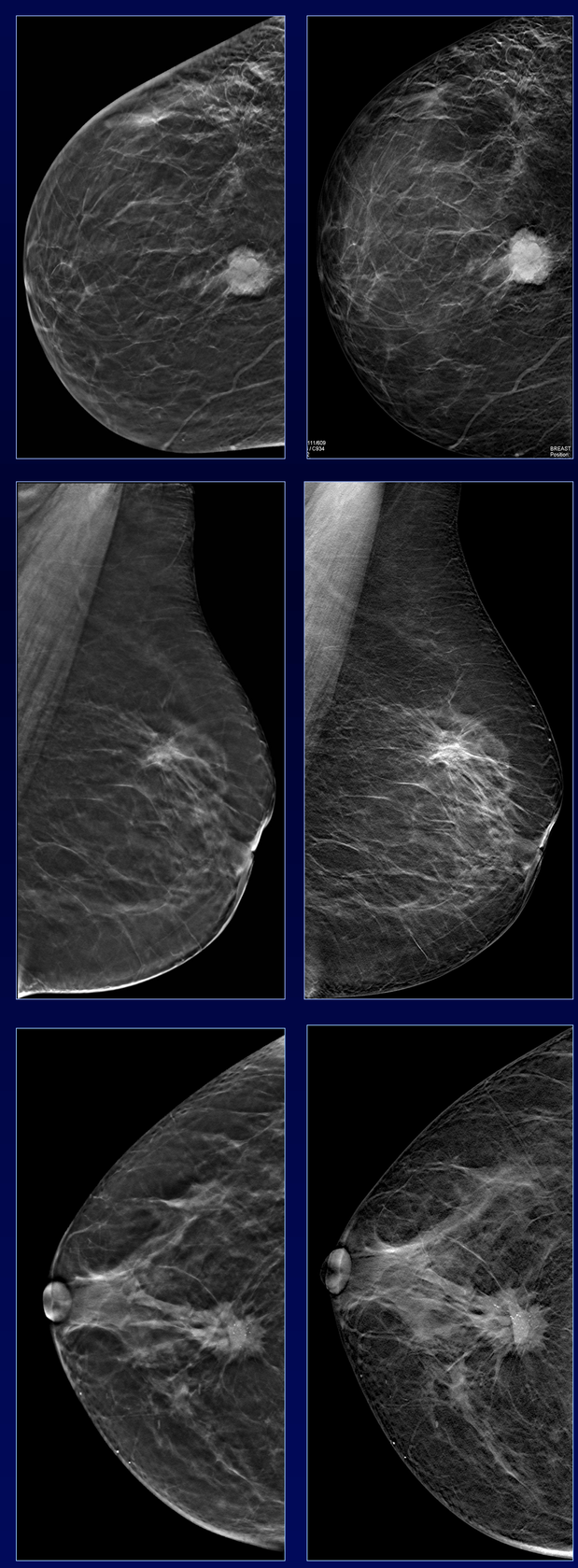

Conventional DBT AGD 2,06 mGy — PhC DBT AGD 0,9 mGy

Conventional DBT AGD 1,59 mGy — PhC DBT AGD 0,6 mGy

Conventional DBT AGD 1,28 mGy — PhC DBT AGD 0,6 mGy

The mean AGD of the conventional DBT was 1.59 mGy for RCC, 1.48 mGy for LCC, 1.77 mGy for RMLO view, 1.69 mGy for LMLO. The mean AGD of the PhC DBT prototype was 0.74 mGy for RCC, 0.71 mGy for LCC, 0.75 mGy for RMLO, 0.73 mGy for LMLO.
The mean AGD delivered by the PhC DBT prototype was about 55% lower than mean AGD delivered by the conventional DBT unit.

Conclusions: Our results demonstrate that PhC technology applied to DBT provides a high imagine quality, similar to a conventional DBT, with a drastic reduction of the AGD